



Idiopathic Pulmonary Fibrosis

UPDATE 2021

**Guidelines for Diagnosis
and Management**

An ATS Pocket Publication



GUIDELINES FOR THE DIAGNOSIS AND MANAGEMENT OF IDIOPATHIC PULMONARY FIBROSIS: UPDATE 2019

AN AMERICAN THORACIC SOCIETY
POCKET PUBLICATION

This pocket guide is a condensed version of the 2011, 2015 and 2018 American Thoracic Society (ATS), European Respiratory Society (ERS), Japanese Respiratory Society (JRS), and Latin American Thoracic Association (ALAT) Evidence-Based Guidelines for Diagnosis and Management of Idiopathic Pulmonary Fibrosis (IPF). This pocket guide was compiled by Ganesh Raghu, MD and Bridget Collins, MD, University of Washington, Seattle from excerpts taken from the published official documents of the ATS. Readers are encouraged to consult the full versions as well as the online supplements, which are available at <http://ajrccm.atsjournals.org/content/183/6/788.long>.

All information in this pocket guide is derived from the 2011, 2015 and 2018 IPF guidelines unless otherwise noted. Some tables and figures are reprinted with the permission from the journals referenced.

Produced in Collaboration with Boehringer Ingelheim Pharmaceuticals, Inc.



Table of contents

List of Figures and Tables	2
List of Abbreviations and Acronyms	3
Definition and Epidemiology	3
Definition	3
Clinical Presentation	4
Incidence/Prevalence	5
Potential Risk Factors	5
Genetic Factors	5
Features of Usual Interstitial Pneumonia Pattern	6
High Resolution Computed Tomography Image Patterns	7
High-Resolution Computed Tomography (HRCT) Scans of Chest	7
HRCT Pattern Suggestive of Diagnosis Alternative To UIP	9
Histopathology Features and Patterns of UIP	10
UIP Patterns: 2018 ATS-ERS-JRS-ALAT Guideline and Fleischner Society Document	13
Guideline Methodology	14
Diagnosis	16
IPF Diagnosis	16
Summary of 2018 ATS-ERS-JRS-ALAT Recommendations Made For Diagnosis of IPF	17
Diagnostic Algorithm for IPF	18
Clinical Course	21
Natural History of IPF	21
Mortality Risks and Acute Exacerbation	24
Treatment	26
Identification and Treatment of Selected Complications and Co-Morbid Conditions in IPF	28
Palliative Care	29
Monitoring the Clinical Course of Disease	29
Summary of Clinical Management of IPF	30
Conclusion	31
References	32

List of figures and tables

Figures

Figure 1: Usual Interstitial Pneumonia (UIP) Pattern	7
Figure 2: Probable Usual Interstitial Pneumonia (UIP) Pattern	7
Figure 3: Indeterminate for Usual Interstitial Pneumonia (UIP) Pattern (Early UIP Pattern)	8
Figure 4: Indeterminate for Usual Interstitial Pneumonia (UIP) Pattern	8
Figure 5: Pattern Suggestive of Alternative Diagnosis	9
Figure 6: Histopathology Demonstrating Usual Interstitial Pneumonia (UIP)	11
Figure 7: Diagnostic Algorithm for Idiopathic Pulmonary Fibrosis (IPF)	18
Figure 8: Natural History of IPF	21
Figure 9: Idiopathic Pulmonary Fibrosis: Rate of FVC Decline/Disease Progression	23
Figure 10: Proposed Conceptual Framework for Evaluation of Acute Respiratory Deterioration in Idiopathic Pulmonary Fibrosis (IPF)	25
Figure 11: Schematic Pathway for Clinical Management of Patients with I (Modified from the 2011 Guideline)	30

Tables

Table 1: High Resolution Computed Tomography Image Patterns	6
Table 2: High-Resolution Computed Tomography Scanning Technique and Parameters	10
Table 3: Histopathology Patterns and Features	12
Table 4: Comparison of Radiographic and Histopathologic Diagnostic Components for IPF Proposed by the 2018 IPF Guideline and the Fleischner Society White Paper	13
Table 5: Quality of Evidence Determination	14
Table 6: Quality of the Evidence Rating and Implications	15
Table 7: Implications of Strong and Conditional Recommendations	15
Table 8: Idiopathic Pulmonary Fibrosis Diagnosis Based Upon HRCT and Biopsy Patterns	20
Table 9: Selected Features Associated with Increased Risk of Mortality in IPF	24
Table 10: Proposed Definition and Diagnostic Criteria for Acute Exacerbation of Idiopathic Pulmonary Fibrosis	24
Table 11: Pharmacological Treatment Recommendations (Updated in the 2015 Guideline)	26
Table 12: Other Treatment Recommendations as Per the 2011 IPF Guideline (These Recommendations were not Updated in the 2015 Guideline)	27

All information in this pocket guide is derived from the 2011, 2015 and 2018 IPF guidelines unless otherwise noted. Tables and figures are referenced so the reader can look up the original document published for further reading.

List of abbreviations and acronyms

6MW: 6-minute-walk test

ALAT = Latin American Thoracic Association

ATS = American Thoracic Society

BAL: Bronchoalveolar lavage

CCL18: Chemokine (C-C motif) ligand 18

CHP: Chronic hypersensitivity pneumonitis

CPI: Composite physiologic index

CT: Computed tomography

DLCO: Diffusing capacity for carbon monoxide

dx: Diagnosis

EBV: Epstein-Barr virus

ERS: European Respiratory Society

FEV1: Forced expiratory volume in 1 second

FVC: Forced vital capacity

GER: Gastroesophageal reflux

GERD: Gastroesophageal reflux disease

GGO: Ground-glass opacities

GRADE: Grading of Recommendations Assessment, Development and Evaluation

HRCT: High-resolution computed tomography

hTERT: Human telomerase reverse transcriptase

hTR: Human telomerase RNA

IIP: Idiopathic interstitial pneumonia

ILD: Interstitial lung disease

IPF: Idiopathic pulmonary fibrosis

JRS: Japanese Respiratory Society

KL-6: Krebs von den Lungen-6

MDD: Multidisciplinary discussion

MMP: Matrix metalloproteinase

NAC: N-acetyl-cysteine

NSIP: Nonspecific interstitial pneumonia

OSA: Obstructive sleep apnea

P(A-a)O₂: Alveolar-arterial oxygen difference in partial pressures

PH: Pulmonary hypertension

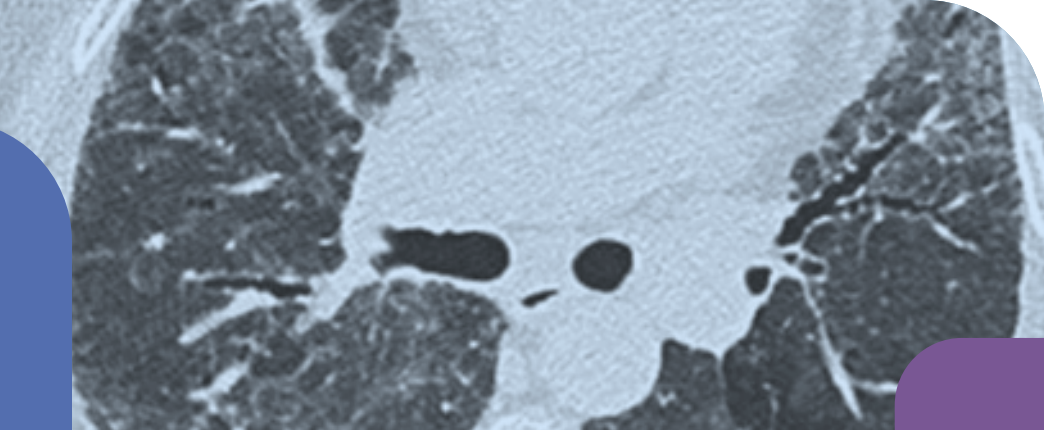
QoL: Quality of life

RCT: Randomized controlled trial

TLC: Total lung capacity

UIP: Usual interstitial pneumonia

VATS: Video-assisted thoracoscopic surgery



Definition and Epidemiology

- Idiopathic pulmonary fibrosis (IPF) is a specific form of chronic, progressive fibrosing interstitial pneumonia of unknown cause, occurring primarily in older adults, limited to the lungs, and associated with the histopathologic and/or radiologic pattern of usual interstitial pneumonia (UIP) defined in (Table 1; Table 3).¹⁻³
- The diagnosis of IPF requires the exclusion of other forms of interstitial pneumonia including other idiopathic interstitial pneumonias (IIP) and interstitial lung disease (ILD) associated with environmental exposure, medication, or connective tissue disease.

Clinical Presentation

- IPF should be considered in all adult patients with unexplained chronic exertional dyspnea, and commonly presents with cough, bibasilar inspiratory crackles, and finger clubbing.
- The incidence of IPF increases with older age, with presentation typically occurring in the sixth and seventh decades.
- IPF is rare in patients younger than 50 years of age.
- IPF is more common among men than among women.
- The majority of patients with IPF have a history of cigarette smoking.

Incidence/Prevalence

- The annual incidence of IPF among US medicare beneficiaries 65 years and older was 93.7 cases per 100,000 person years between 2001 and 2011 and remained stable.⁴
- The annual cumulative prevalence increased to 494.5 cases per 100,000 people in 2011 from 202.2 cases per 100,000 people in 2001.⁴

Potential Risk Factors

- Cigarette smoking (particularly a smoking history of >20 pack-years).
- Abnormal gastroesophageal reflux (GER) through its presumed association with microaspiration.
- Age >60 yrs.
- Male.

Genetic Factors

- Familial IPF represents <5% of all cases. It is clinically and histologically indistinguishable from sporadic IPF, although it may develop at an earlier age.
- Genetic variants within the human telomerase reverse transcriptase (hTERT) or human telomerase RNA (hTR) components of the telomerase gene are found in ≤15% of familial pulmonary fibrosis kindreds and 3% of sporadic IIP cases. At present, there are no genetic factors that are consistently associated with sporadic IPF. Genetic factors reported subsequent to the published 2011 document include MUC5B promoter polymorphism, ABCA3, AKAP13, TOLLIP genotypes, mutations in TERT/TERC and other telomere maintenance components leading to shortened telomeres.

Features of Usual Interstitial Pneumonia Pattern

Table 1: High Resolution Computed Tomography Image Patterns³

UIP	Probable UIP	Indeterminate for UIP	Alternative Diagnosis
<ul style="list-style-type: none"> Subpleural and basal predominant; distribution is often heterogeneous Honeycombing with or without peripheral traction bronchiectasis or bronchiolectasis 	<ul style="list-style-type: none"> Subpleural and basal predominant; distribution is often heterogeneous Reticular pattern with peripheral traction bronchiectasis or bronchiolectasis May have mild GGO 	<ul style="list-style-type: none"> Subpleural and basal predominant Subtle reticulation; may have mild GGO or distortion (“early UIP pattern”) CT features and/or distribution of lung fibrosis that do not suggest any specific etiology (“truly indeterminate for UIP”) 	<ul style="list-style-type: none"> Findings suggestive of another diagnosis, including: <p>CT features:</p> <ul style="list-style-type: none"> Cysts Marked mosaic attenuation Predominant GGO Profuse micronodules Centrilobular nodules Nodules Consolidation <p>Predominant distribution:</p> <ul style="list-style-type: none"> Peribronchovascular Perilymphatic Upper or mid-lung <p>Other:</p> <ul style="list-style-type: none"> Pleural plaques (consider asbestosis) Dilated esophagus (consider CTD) Distal clavicular erosions (consider RA) Extensive lymph node enlargement (consider other etiologies) Pleural effusions, pleural thickening (consider CTD/ drugs)

High-Resolution Computed Tomography (HRCT) Scans of Chest

Figure 1: Usual Interstitial Pneumonia (UIP) Pattern³

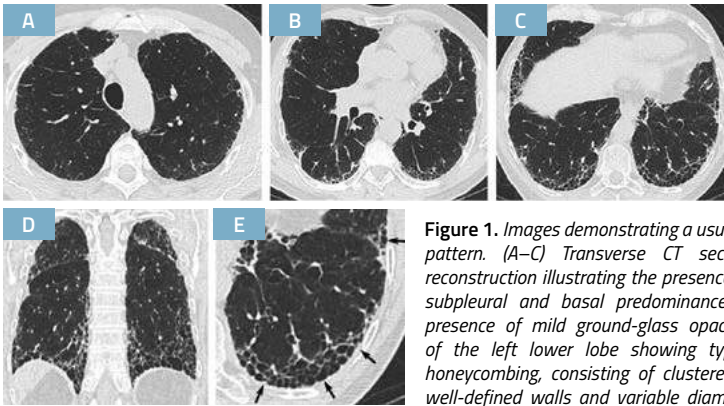


Figure 1. Images demonstrating a usual interstitial pneumonia pattern. (A–C) Transverse CT section and (D) coronal reconstruction illustrating the presence of honeycombing with subpleural and basal predominance. Note the concurrent presence of mild ground-glass opacity. (E) Magnified view of the left lower lobe showing typical characteristics of honeycombing, consisting of clustered cystic airspaces with well-defined walls and variable diameters, seen in single or multiple layers (arrows).

Figure 2: Probable Usual Interstitial Pneumonia (UIP) Pattern³

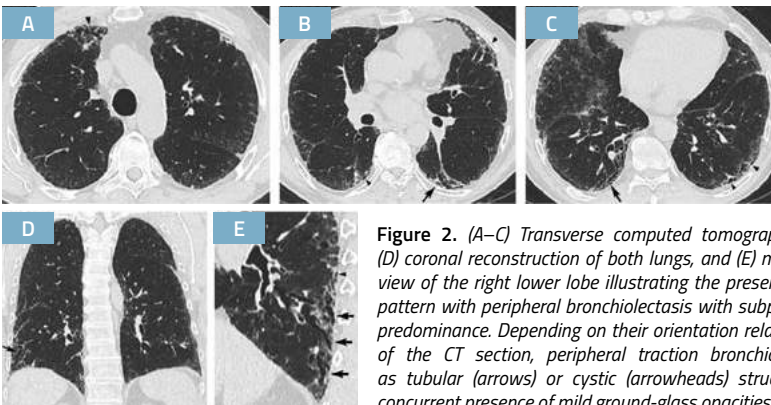


Figure 2. (A–C) Transverse computed tomography (CT) section, (D) coronal reconstruction of both lungs, and (E) magnified sagittal view of the right lower lobe illustrating the presence of a reticular pattern with peripheral bronchiolectasis with subpleural and basal predominance. Depending on their orientation relative to the plane of the CT section, peripheral traction bronchiolectasis appear as tubular (arrows) or cystic (arrowheads) structures. Note the concurrent presence of mild ground-glass opacities in the subpleural areas of both lungs and the absence of honeycombing. UIP was proven at histology.

Figure 3: Indeterminate for Usual Interstitial Pneumonia (UIP) Pattern (Early UIP Pattern)³

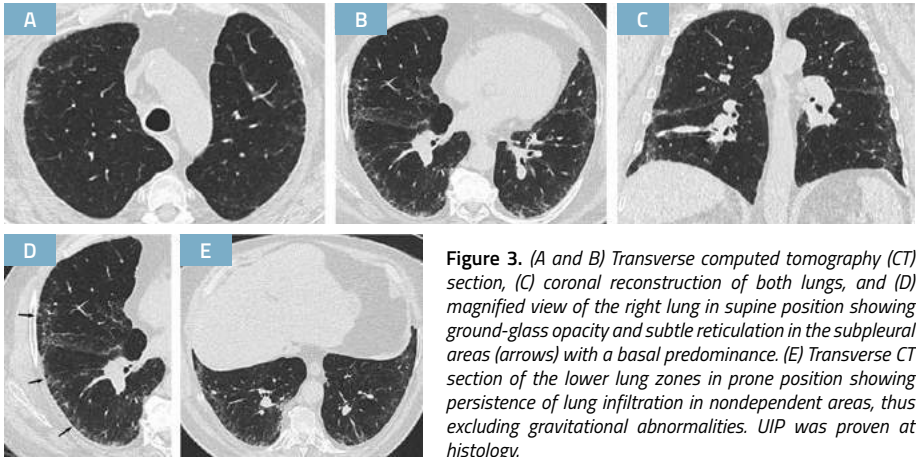
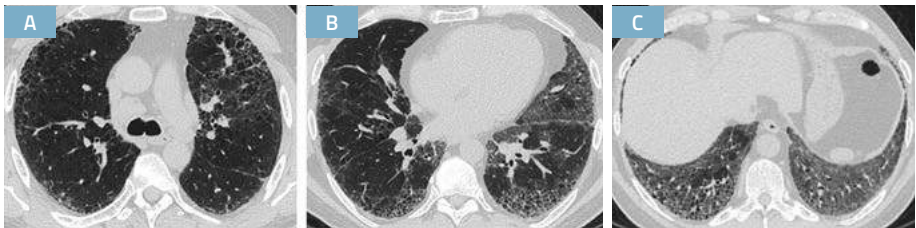


Figure 4: Indeterminate for Usual Interstitial Pneumonia (UIP) Pattern³



HRCT Pattern Suggestive of Diagnosis Alternative to UIP

Figure 5: Pattern Suggestive of Alternative Diagnosis³

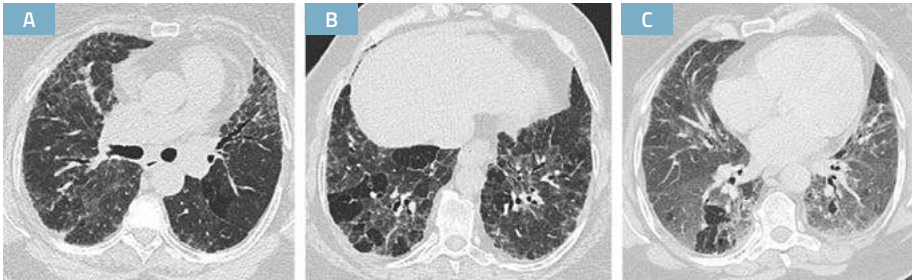

Figure 5. Suggestive of an alternative diagnosis for lung fibrosis. (A and B) Transverse CT sections obtained at deep inspiration showing disseminated lung infiltration, sparing some secondary pulmonary lobules in lung bases. (C) Transverse CT section obtained at expiration confirming lobular air trapping, all findings being highly suggestive of chronic hypersensitivity pneumonitis.

Table 2: High-Resolution Computed Tomography Scanning Technique and Parameters³

Recommended Scanning Protocol	Advantages of Updated Recommendations
<p>1 Noncontrast examination</p>	<p>—</p>
<p>2. Volumetric acquisition with selection of:</p> <ul style="list-style-type: none"> ▪ Sub-millimetric collimation ▪ Shortest rotation time ▪ Highest pitch ▪ Tube potential and tube current appropriate to patient size: <ul style="list-style-type: none"> ▪ Typically 120 kVp and ≤ 240 mAs ▪ Lower tube potentials (e.g., 100 kVp) with adjustment of tube current encouraged for thin patients ▪ Use of techniques available to avoid unnecessary radiation exposure (e.g., tube current modulation) 	<p>A. Acquisition covering the entire lung volume (vs. analysis of 10% of lung volume with sequential scanning)</p> <ul style="list-style-type: none"> ▪ No risk of missing subtle infiltrative abnormalities ▪ Possibility of multiplanar reformations, helpful for analysis of the ILD pattern and predominant distribution of lung changes ▪ Possibility of post-processing to optimize detection of subtle hypoattenuated lesions (minimum intensity projection) and micronodular infiltration (maximum intensity projection) ▪ Possibility of detection of additional lesions (e.g., incidental identification of lung nodule or focal consolidation in lung fibrosis that may correspond to lung carcinoma) ▪ Optimal to assess progression or improvement in patient's follow-up <p>B. Dramatic increase in temporal resolution and speed of data acquisition</p> <ul style="list-style-type: none"> ▪ Motion-free images <p>C. Availability of numerous dose-reduction tools</p>
<p>3. Reconstruction of thin-section CT images (≤ 1.5 mm):</p> <ul style="list-style-type: none"> ▪ Contiguous or overlapping ▪ Using a high-spatial-frequency algorithm ▪ Iterative reconstruction algorithm if validated on the CT unit (if not, filtered back projection) 	<p>—</p>
<p>4. Number of acquisitions:</p> <ul style="list-style-type: none"> ▪ Supine: inspiratory (volumetric) ▪ Supine: expiratory (can be volumetric or sequential) ▪ Prone: only inspiratory scans (can be sequential or volumetric); optional (<i>see text</i>) ▪ Inspiratory scans obtained at full inspiration 	<p>A. Expiratory scans useful to detect air trapping</p> <p>B. Prone scans allow analysis of peripheral lung changes without dependent lung atelectasis that may be mistaken for abnormal lung infiltration or mimic disease (e.g., pseudohoneycombing when combined with paraseptal emphysema)</p> <p>C. Inadequate inspiration increases lung attenuation (which should not be interpreted as ground-glass attenuation) and is responsible for dependent lung atelectasis (which may mimic abnormal lung infiltration or mask subtle abnormalities)</p>
<p>5. Recommended radiation dose for the inspiratory volumetric acquisition:</p> <ul style="list-style-type: none"> ▪ 1–3 mSv (i.e., “reduced” dose) ▪ Strong recommendation to avoid “ultralow-dose CT” (< 1 mSv) 	<p>A. Considerable dose reduction compared to conventional scanning</p>

Histopathology Features And Patterns of UIP

Histopathology Features

- The histopathologic hallmark and chief diagnostic criterion is a heterogeneous appearance at low magnification in which areas of fibrosis of UIP change alternate with areas of less affected or normal parenchyma (Figure 6; Table 3).

Figure 6: Histopathology Demonstrating Usual Interstitial Pneumonia (UIP)³

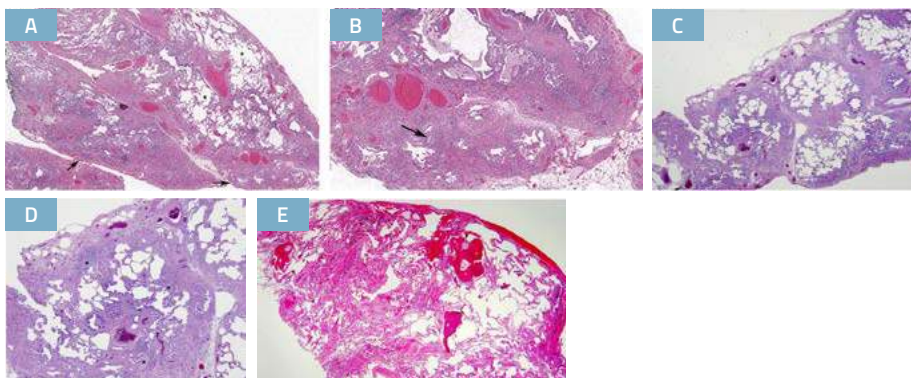


Figure 6. (A) Low-magnification photomicrograph showing classical UIP/idiopathic pulmonary fibrosis (IPF) pattern characterized by dense fibrosis with a predilection for subpleural and paraseptal parenchyma with associated architectural distortion in the form of microscopic honeycomb change (arrow) juxtaposed with relatively unaffected lung parenchyma (*). Visceral pleura is seen in the upper portion of the figure. (B) Higher-magnification photomicrograph showing subpleural scarring and honeycomb change with associated fibroblast foci (arrow). (C) Low-magnification photomicrograph showing probable UIP/IPF pattern characterized by subpleural and paraseptal predominant patchwork fibrosis that is less well developed and lacks the degree of associated architectural distortion in the form of either destructive scarring or honeycomb change illustrated in A and B. (D) Higher-magnification photomicrograph showing patchy fibrosis and fibroblast foci (*) but without the extent of scarring and honeycomb change illustrated in A and B. (E) Indeterminate for UIP/IPF pattern in which there is mild nonspecific fibrosis that lacks a well-developed patchy and predominantly subpleural/paraseptal distribution, architectural distortion, and fibroblast foci characteristic of classical UIP/IPF. There is associated osseous metaplasia, a common but nonspecific finding in UIP. Although these findings are not diagnostic, they do not preclude a diagnosis of UIP/IPF in a patient with supportive clinical and radiological findings.

Table 3: Histopathology Patterns and Features³

UIP	Probable UIP	Indeterminate for UIP	Alternative Diagnosis
<ul style="list-style-type: none"> ▪ Dense fibrosis with architectural distortion (i.e., destructive scarring and/or honeycombing) ▪ Predominant subpleural and/or paraseptal distribution of fibrosis ▪ Patchy involvement of lung parenchyma by fibrosis ▪ Fibroblast foci ▪ Absence of features to suggest an alternative diagnosis 	<ul style="list-style-type: none"> ▪ Some histologic features from column 1 are present but to an extent that precludes a definite diagnosis of UIP/IPF <p>And</p> <ul style="list-style-type: none"> ▪ Absence of features to suggest an alternate diagnosis <p>Or</p> <ul style="list-style-type: none"> ▪ Honeycombing only 	<ul style="list-style-type: none"> ▪ Fibrosis with or without architectural distortion, with features favoring either a pattern other than UIP or features favoring UIP secondary to another cause* ▪ Some histologic features from column 1, but with other features suggesting an alternative diagnosis** 	<ul style="list-style-type: none"> ▪ Features of other histologic patterns of IIPs (e.g., absence of fibroblast foci or loose fibrosis) in all biopsies ▪ Histologic findings indicative of other diseases (e.g., hypersensitivity pneumonitis, Langerhans cell histiocytosis, sarcoidosis, LAM)

* *Granulomas, hyaline membranes (other than when associated with acute exacerbation of IPF, which may be the presenting manifestation in some patients), prominent airway-centered changes, areas of interstitial inflammation lacking associated fibrosis, marked chronic fibrous pleuritis, organizing pneumonia. Such features may not be overt or easily seen to the untrained eye and often need to be specifically sought.*

** *Features that should raise concerns about the likelihood of an alternative diagnosis include a cellular inflammatory infiltrate away from areas of honeycombing, prominent lymphoid hyperplasia including secondary germinal centers, and a distinctly bronchiolocentric distribution that could include extensive peribronchiolar metaplasia.*

UIP Patterns: 2018 ATS -ERS-JRS-ALAT Guideline And Fleischner Society Document

Table 4: Comparison of Radiographic and Histopathologic Diagnostic Components for IPF Proposed by the 2018 IPF Guideline and the Fleischner Society White Paper⁵

ATS/ERS/JRS/ALAT Clinical Practice Guidelines		Fleischner White Paper Consensus Statement
Age Limit for Increased Diagnostic Confidence: 60		
HRCT Pattern	UIP	Typical UIP
	<ul style="list-style-type: none"> Subpleural and basal predominance Presence of honeycombing with or without peripheral traction bronchiectasis <i>Biopsy NOT recommended</i> 	<ul style="list-style-type: none"> Subpleural and basal predominance Presence of honeycombing with or without peripheral traction bronchiectasis <i>Biopsy NOT recommended</i>
	Probable UIP	
	<ul style="list-style-type: none"> Subpleural and basal predominance Presence of peripheral traction bronchiectasis <i>Biopsy recommended [conditional]</i> 	<ul style="list-style-type: none"> Subpleural and basal predominance Presence of peripheral traction bronchiectasis <i>Biopsy NOT recommended</i>
	Intermediate for UIP	
	<ul style="list-style-type: none"> Subpleural and basal predominant May have mild GGO or distortion <i>Biopsy recommended</i> 	<ul style="list-style-type: none"> Variable or diffuse Features suggestive of non-UIP pattern <i>Biopsy recommended</i>
Alternative Diagnosis		Most Consistent with Non-IPF Diagnosis
<ul style="list-style-type: none"> Findings suggestive of another diagnosis <i>Biopsy recommended</i> 	<ul style="list-style-type: none"> Findings suggestive of another diagnosis <i>Biopsy recommended</i> 	
Histopathology Pattern	UIP	Definite UIP
	<ul style="list-style-type: none"> Dense fibrosis with architecture remodeling Predominant subpleural or paraseptal distribution of fibrosis Patchy lung involvement by fibrosis Presence of fibroblastic foci 	<ul style="list-style-type: none"> Dense fibrosis with architecture remodeling Predominant subpleural or paraseptal distribution of fibrosis Patchy lung involvement by fibrosis Presence of fibroblastic foci
	Probable UIP	
	<ul style="list-style-type: none"> Honeycomb fibrosis only Fibroblastic foci may or may not be present 	<ul style="list-style-type: none"> Honeycomb fibrosis only Fibroblastic foci may or may not be present
	Intermediate UIP	
	<ul style="list-style-type: none"> Fibrosis with or without architecture distortion Some histological features from the UIP pattern 	<ul style="list-style-type: none"> Occasional foci of centrilobular injury or scarring Rare granulomas or giant cells Minor degree of lymphoid hyperplasia or diffuse inflammation Diffuse homogeneous fibrosis favoring fibrotic nonspecific interstitial pneumonia
Alternative Diagnosis		Features Most Consistent with an Alternative Diagnosis
<ul style="list-style-type: none"> Histopathological findings indicative of other diseases 	<ul style="list-style-type: none"> A UIP pattern with ancillary features strongly suggesting an alternative diagnosis A non-UIP pattern 	

This table is reproduced with permission from the ERS.⁵ Criteria have been summarized for purposes of comparison.

Guideline Methodology

- Relevant section topics and questions were identified by committee members after which, additional input was sought from general pulmonologists in the community and at academic centers. An evidence profile was created for each question using the Grading of Recommendations Assessment, Development and Evaluation (GRADE) methodology. The quality of evidence (Table 5; Table 6) was determined according to the ATS GRADE criteria. The strength of the recommendations is either “strong” or “conditional” based on the quality of evidence and the voting of the committee members (Table 7).

Table 5: Quality of Evidence Determination¹

Quality of Evidence	Study Design	Lower If	Higher If
<ul style="list-style-type: none"> ▪ High ▪ Moderate ▪ Low ▪ Very low 	<ul style="list-style-type: none"> ▪ RCT ▪ Downgraded RCT or upgraded observational study ▪ Well-conducted observational study with control groups ▪ Any other evidence (e.g., case reports, case series) 	<ul style="list-style-type: none"> ▪ Limitation in study quality ▪ Indirectness ▪ Important inconsistency ▪ Sparse or imprecise data ▪ High probability of publication bias 	<ul style="list-style-type: none"> ▪ Strong association, no plausible confounders ▪ Evidence of a dose–response gradient ▪ Plausible confounders would have reduced the effect

Table 6: Quality of the Evidence Rating and Implications¹

Quality of the Evidence (GRADE)	The quality of the evidence is a judgment about the extent to which we can be confident that the estimates of effect are correct. These judgments are made using the GRADE system, and are provided for each outcome. The judgments are based on the type of study design (randomized trials versus observational studies), the risk of bias, the consistency of the results across studies, and the precision of the overall estimate across studies. For each outcome, the quality of the evidence is rated as high, moderate, low, or very low using the following definitions:
High ●●●●	Further research is very unlikely to change the Committee’s confidence in the estimate of effect
Moderate ●●●○	Further research is likely to have an important impact on the Committee’s confidence in the estimate of effect and may change the estimate
Low ●●○○	Further research is very likely to have an important impact on the Committee’s confidence in the estimate of effect and is likely to change the estimate
Very Low ●○○○	The Committee is very uncertain about the estimate

Table 7: Implications of Strong and Conditional Recommendations³

	Strong Recommendation (“We recommend...”)	Conditional Recommendation (“We suggest...”)
For Patients	The overwhelming majority of individuals in this situation would want the recommended course of action and only a small minority would not.	The majority of individuals in this situation would want the suggested course of action, but a sizable minority would not.
For Clinicians	The overwhelming majority of individuals should receive the recommended course of action. Adherence to this recommendation according to the guideline could be used as a quality criterion or performance indicator. Formal decision aids are not likely to be needed to help individuals make decisions consistent with their values and preferences.	Different choices will be appropriate for different patients, and you must help each patient arrive at a management decision consistent with her or his values and preferences. Decision aids may be useful to help individuals make decisions consistent with their values and preferences. Clinicians should expect to spend more time with patients when working toward a decision.
For Policy Makers	The recommendation can be adapted as policy in most situations, including for use as performance indicators.	Policy making will require substantial debates and involvement of many stakeholders. Policies are also more likely to vary between regions. Performance indicators would have to focus on the fact that adequate deliberation about the management options has taken place.

Diagnosis

IPF Diagnosis

- IPF is a specific form of chronic progressive fibrosing interstitial pneumonia of unknown cause

“The patient suspected to have IPF”

Typical Patient:

- Male >60 yrs., current or ex-cigarette smoker with insidious onset of cough, exertional dyspnea, basilar crackles and radiological evidence of fibrosis in lower lobes. (Rarely: Patients manifest acute exacerbation on an initial presentation).
- Middle aged adults (>40 yrs.), especially patients with risks for familial pulmonary fibrosis and genetic predisposition factors for IPF can rarely present with same clinical scenario as the “typical” patients with IPF.
- **Diagnosis of IPF requires:**
 1. Exclusion of known causes of ILD (e.g., domestic and occupational environmental exposures, connective tissue disease, drug toxicity and EITHER (2) or (3).
 2. Presence of HRCT pattern of UIP (sufficient for diagnosis of IPF in the appropriate clinical setting; i.e. without surgical lung biopsy).
 3. Specific combination of HRCT and histopathology patterns in patients subjected to lung tissue sampling (Figure 8) (emphasis on multidisciplinary discussion*).

* For patients with newly detected ILD of apparently unknown cause who are clinically suspected to have IPF, MDD is suggested for diagnostic decision making (conditional recommendation, very low quality of evidence).

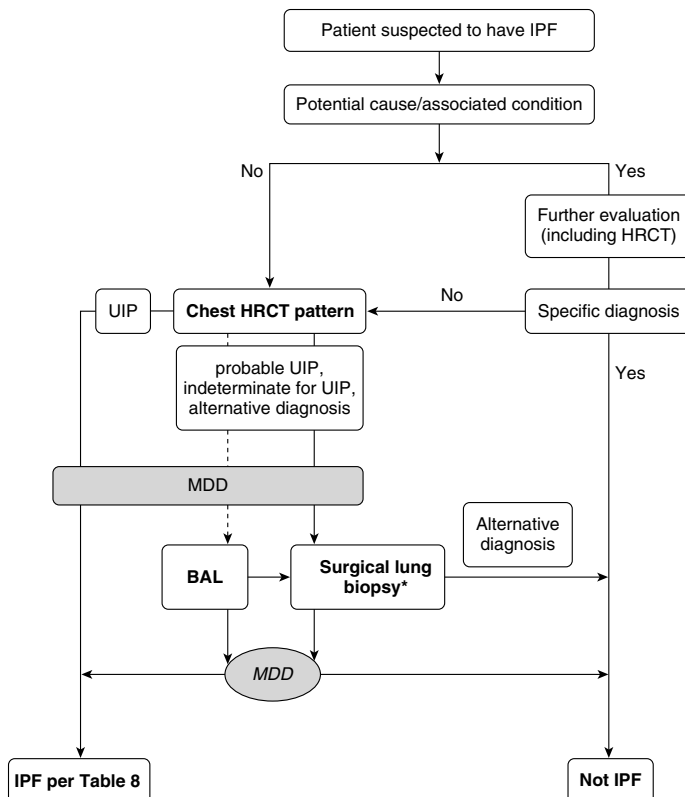
Summary of 2018 ATS-ERS-JRS-ALAT Recommendations Made for Diagnosis of IPF

- I. **For adult patients with newly detected ILD of apparently unknown cause who are clinically suspected of having IPF, the panel recommended the following as ‘motherhood statements’:**
 1. Elicit a detailed history of both medication use and environmental exposures at home, work, and other places the patient frequently visits to exclude potential causes of ILD.
 2. Detailed serological testing beyond ANA (including myositis panel) to exclude connective tissue disease as a potential cause of the ILD.
- II. **For patients with newly detected ILD of apparently unknown cause who are clinically suspected of having IPF and have a HRCT pattern of UIP:**
 - The panel recommended against transbronchial, transbronchial cryobiopsy or surgical lung biopsy (strong recommendation, very low quality evidence).
 - The panel suggested NOT performing cellular analysis of their BAL fluid (conditional recommendation, very low quality of evidence).
- III. **For patients with newly detected ILD of apparently unknown cause who are clinically suspected of having IPF and have a HRCT pattern of probable UIP, indeterminate for UIP, or an alternative diagnosis, the panel suggested:**
 - Perform bronchoalveolar lavage (BAL) fluid for cellular analyses (conditional recommendation, very low quality of evidence).
 - Surgical lung biopsy (SLB) in patients whose surgical risks are low (conditional recommendation, very low quality of evidence).
 - The panel made no recommendation for or against transbronchial lung biopsy (TBBx).
 - The panel made no recommendation for or against transbronchial lung cryobiopsy.

- IV. For adult patients with newly detected ILD of apparently unknown cause who are clinically suspected of having IPF, the panel emphasized the need for multidisciplinary discussions (MDD) during diagnostic evaluation at several steps (see algorithm below).
- V. Routine testing of serum biomarkers (MMP7, SPD, KL-6, CCL-18) is not recommended to distinguish IPF from other forms of ILD (strong recommendation, low quality evidence) regardless of CT pattern.

Diagnostic Algorithm for IPF

Figure 7: Diagnostic Algorithm for Idiopathic Pulmonary Fibrosis (IPF)³



- Patients with suspected IPF (i.e., unexplained symptomatic or asymptomatic bilateral pulmonary infiltrates on a chest radiograph or chest computed tomography [CT] scan, bibasilar inspiratory crackles, and age older than 60 yrs.), unexplained dyspnea on exertion, and/or cough with evidence of interstitial lung disease (ILD) should be carefully evaluated for potential and/or identifiable causes of ILD, such as domestic and occupational environmental exposures, connective tissue disease (CTD), or drug toxicity. Middle-aged adults (>40 yrs. and <60 yrs.), especially patients with risks for familial pulmonary fibrosis, can rarely present with the otherwise same clinical scenario as the typical patient older than 60 yrs. If a potential cause for ILD is identified, the patient should undergo a thorough evaluation to confirm or exclude other known causes, such as hypersensitivity pneumonitis, CTD, pneumoconiosis, and iatrogenic causes (e.g., drug toxicity, irradiation). If a specific diagnosis is not made or no potential cause for ILD is identified, further evaluation is influenced by the patterns of high-resolution CT (HRCT) images of the chest and supportive clinical findings surfaced in the course of multidisciplinary discussion to ascertain or exclude the diagnosis of IPF. IPF is diagnosed if the appropriate combination of HRCT patterns and histopathological patterns are present.

**Surgical lung biopsy is not indicated in patients at high risk for intra-, peri-, or postoperative complications (e.g., severe hypoxemia at rest and/or severe pulmonary hypertension with a diffusion capacity less than 25% after correction for hemoglobin). Surgical lung biopsy may be unnecessary in some familial cases.*

- The panel has no recommendation for or against conventional transbronchial biopsy and/or cryobiopsy; however, if performed, histopathology may be sufficient in selected patients (consult the full version for the remarks and discussions regarding lung biopsy available at <http://ajrccm.atsjournals.org/content/183/6/788.long>).

Table 8: Idiopathic Pulmonary Fibrosis Diagnosis Based Upon HRCT and Biopsy Patterns³

IPF Suspected*		Histopathology Pattern			
		UIP	Probable UIP	Indeterminate for UIP	Alternative Diagnosis
HRCT Pattern	UIP	IPF	IPF	IPF	Non-IPF dx
	Probable UIP	IPF	IPF	IPF (Likely)**	Non-IPF dx
	Indeterminate for UIP	IPF	IPF (Likely)**	Indeterminate for IPF***	Non-IPF dx
	Alternative Diagnosis	IPF (Likely)**/ Non-IPF dx	Non-IPF dx	Non-IPF dx	Non-IPF dx

* **Clinically suspected of having IPF** = Unexplained symptomatic or asymptomatic patterns of bilateral pulmonary fibrosis on a chest radiograph or chest computed tomography, bibasilar inspiratory crackles, and age >60 yrs. (Middle-aged adults [>40 yrs. and <60 yrs.], especially patients with risks for familial pulmonary fibrosis, can rarely present with the otherwise same clinical scenario as the typical patient >60 yrs.)

** **IPF is the likely diagnosis when any of the following features are present:**

- Moderate-to-severe traction bronchiectasis/bronchiolectasis (defined as mild traction bronchiectasis/bronchiolectasis in four or more lobes including the lingual as a lobe, or moderate to severe traction bronchiectasis in two or more lobes) in a man >50 yrs. or in a woman >60 yrs.
- Extensive (>30%) reticulation on HRCT and an age >70 yrs.
- Increased neutrophils and/or absence of lymphocytosis in BAL fluid
- Multidisciplinary discussion reaches a confident diagnosis of IPF

*** **Indeterminate for IPF**

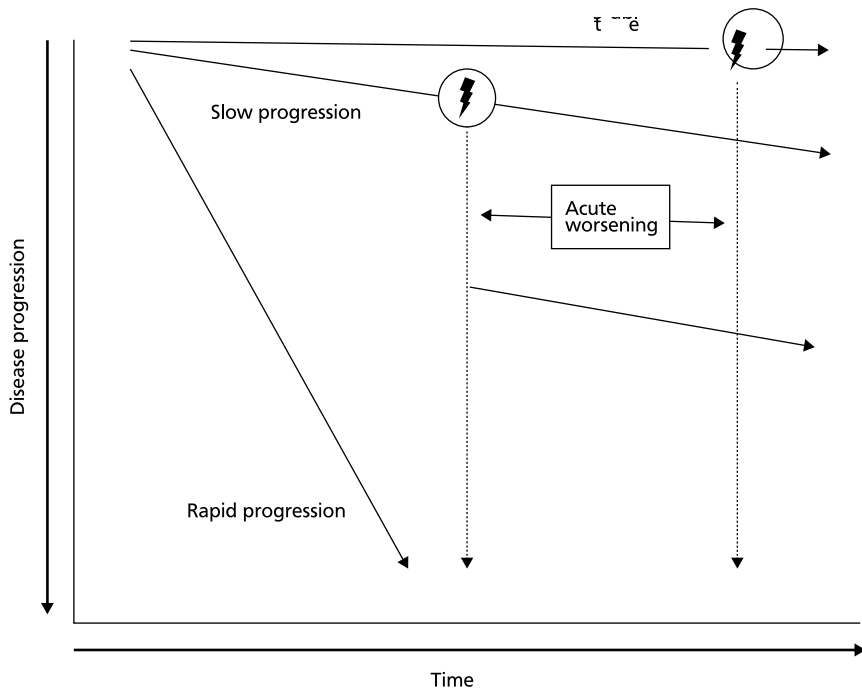
- Without an adequate biopsy is unlikely to be IPF
- With an adequate biopsy may be reclassified to a more specific diagnosis after multidisciplinary discussion and/or additional consultation

Clinical Course

Diagnostic Algorithm for IPF

- IPF is a fatal lung disease; the natural history is variable and unpredictable:

Figure 8: Natural History of IPF¹

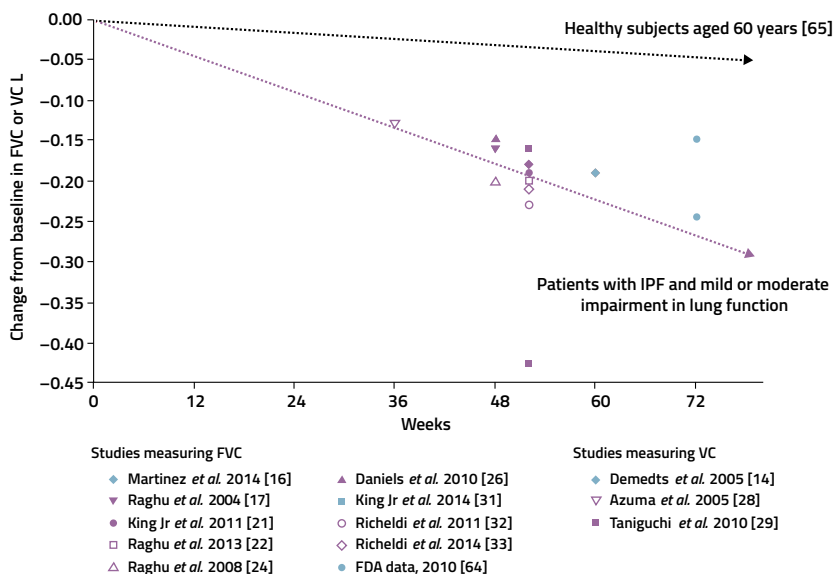


- There appear to be several possible natural histories for patients with IPF. The majority of patients experience a slow but steady worsening of their disease (“Slow progression”). Some patients remain stable (“Stable”), while others have an accelerated decline (“Rapid progression”). A minority of patients may experience unpredictable acute worsening of their disease (lightning bolt), either from a secondary complication such as pneumonia, or for unrecognized reasons. This event may be fatal or may leave patients with substantially worsened disease. The relative frequency of each of these natural histories is unknown.

Vital Statistics

- Deaths from pulmonary fibrosis increase with increasing age.
- Evidence suggests that mortality from pulmonary fibrosis has increased over the past two decades.
- The mortality burden attributable to IPF is higher than that of some cancers.
- Recent evidence suggests that mortality from IPF in the United States is greater in the winter months.
- Progressive lung disease is responsible for 60% of IPF deaths.
- Additional causes of IPF-related morbidity and mortality include coronary artery disease, pulmonary embolism, and lung cancer.

Figure 9: Idiopathic Pulmonary Fibrosis: Rate of FVC Decline/Disease Progression⁶



- Natural course of lung function decline in placebo-treated patients with idiopathic pulmonary fibrosis (IPF) from the time of enrollment in clinical trials to 72 weeks. The decline in forced vital capacity (FVC) from baseline is approximately 150–200 mL·year⁻¹ (0.15–0.2 L·year⁻¹). The symbols denote the mean (or median [21, 22]) change from baseline in FVC [16, 17, 21, 22, 24, 26, 31–33, 64] or vital capacity (VC) [14, 28, 29] in the placebo groups of Phase-II and Phase-III clinical trials in patients with IPF. The black line denotes the mean decline in FVC in healthy subjects aged 60 yrs. based on FVC measurements taken between 1987–1989, 1990–1992 and 2011–2013 [65].
- This figure and legend are reproduced with permission from the ERJ.⁶ The numbers within the [] in this legend are the citation numbers referenced in the article published.⁶

Mortality Risks And Acute Exacerbation

Table 9: Selected Features Associated with Increased Risk of Mortality in IPF¹

Baseline factors*	Longitudinal factors
Level of dyspnea**	Increase in level of dyspnea**
DLCO, 40% predicted	Decrease in FVC by >10% absolute value
Desaturation <88% during 6MWT	Decrease in DLCO by >15% absolute value
Extent of honeycombing on HRCT**	Worsening of fibrosis on HRCT**
Pulmonary hypertension	Pulmonary hypertension

* Baseline FVC is of unclear predictive value.

** Currently, there is no uniformity in approach to quantification.

- 5-10% of patients with IPF may have an acute exacerbation of IPF, defined below. Acute exacerbation of IPF often results in respiratory failure, hospitalization and death.

Table 10: Proposed Definition and Diagnostic Criteria for Acute Exacerbation of Idiopathic Pulmonary Fibrosis⁷

Definition

- An acute, clinically significant respiratory deterioration characterized by evidence of new widespread alveolar abnormality

Revised Diagnostic Criteria

- Previous or concurrent diagnosis of IPF*
- Acute worsening or development of dyspnea typically, 1-month duration
- Computed tomography with new bilateral ground-glass opacity and/or consolidation superimposed on a background pattern consistent with usual interstitial pneumonia pattern**
- Deterioration not fully explained by cardiac failure or fluid overload

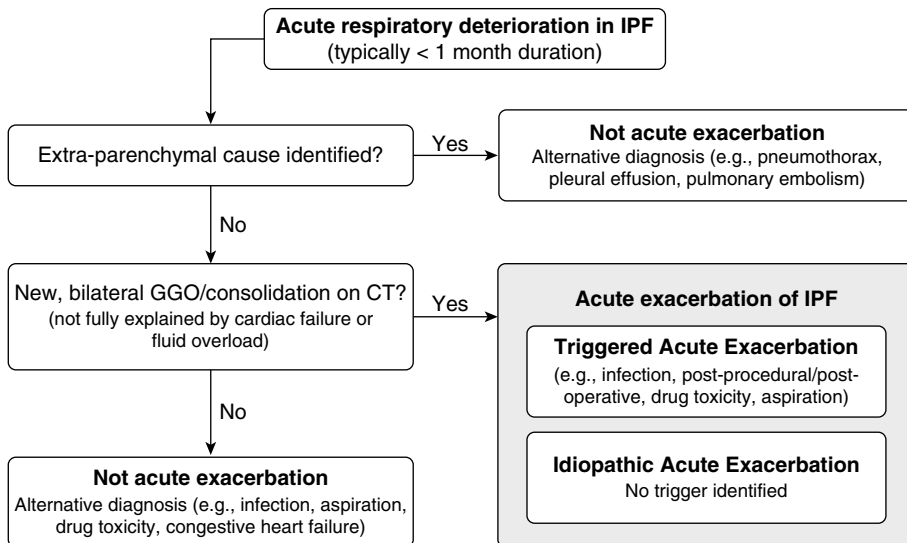
Events that are clinically considered to meet the definition of acute exacerbation of IPF but fail to meet all four diagnostic criteria owing to missing computed tomography data should be termed "suspected acute exacerbations."

** If the diagnosis of IPF is not previously established, this criterion can be met by the presence of radiologic and/or histopathologic changes consistent with usual interstitial pneumonia pattern on the current evaluation.*

*** If no previous computed tomography is available, the qualifier "new" can be dropped.*

This table is reproduced with permission from AJRCCM.⁷

Figure 10: Proposed Conceptual Framework for Evaluation of Acute Respiratory Deterioration in Idiopathic Pulmonary Fibrosis (IPF)⁷



- Acute respiratory deterioration of IPF (defined as “typically ,1 month in duration”) can be categorized as extraparenchymal (e.g., pulmonary embolism, pneumothorax, pleural effusion) or parenchymal. Parenchymal causes that demonstrate new bilateral ground-glass opacification (GGO)/consolidation on computed tomography (CT) that is not fully explained by cardiac failure or fluid overload are categorized as acute exacerbations of IPF, regardless of the presence or absence of a known trigger (e.g., infection). Acute exacerbations are further categorized as triggered acute exacerbation or idiopathic acute exacerbation, depending on whether an underlying trigger for acute exacerbation is found.
- This figure is reproduced with permission from AJRCCM.⁷

Treatment

- Two antifibrotic medications, pirfenidone and nintedanib have been shown to slow the rate of decline in FVC over time among patients with IPF with mild to moderate impairment in pulmonary function. Similar effects have been demonstrated in patients with mild impairment in lung function and those with advanced disease. Treatment with an antifibrotic was given a conditional recommendation for use, moderate confidence in estimate of effect. The recommendation for lung transplantation in appropriate patients with IPF is strong.

Table 11: Pharmacological Treatment Recommendations
(Updated in the 2015 Guideline)

	Strong		Conditional	
	For	Against	For	Against
Nintedanib			X	
Pirfenidone			X	
Antiacid treatment			X	
Dual ERA (bosentan, macitentan)				X
Sildenafil				X
Warfarin		X		
Combination prednisone + azathioprine + N-Acetylcysteine		X		
N-Acetylcysteine				X
Selective ERA (ambrisentan)		X		
Imatinib		X		

Table 12: Other Treatment Recommendations as Per the 2011 IPF Guideline (These Recommendations were not Updated in the 2015 Guideline)

	Strong		Conditional*	
	For**	Against**	For**	Against**
Appropriate patients with IPF should undergo lung transplantation	X			
Supplemental O2 for IPF patients with resting hypoxemia	X			
Pulmonary rehabilitation			X	
Treatment of pulmonary hypertension				X
High dose corticosteroids for acute exacerbation IPF			X	
Corticosteroid monotherapy		X		
Colchicine		X		
Cyclosporine A		X		
Corticosteroid and immunomodulatory therapy (azathioprine or cyclophosphamide)		X		
Etanercept		X		
Anticoagulation				X
Mechanical ventilation in patients with respiratory failure due to IPF				X

* Conditional was stated as "weak" in the 2011 guideline

** "For" was stated as "YES" and "Against" as "NO" in the 2011 guideline

Identification and Treatment of Selected Complications and Co-morbid Conditions in IPF

- **While obesity, emphysema, lung cancer and obstructive sleep apnea (OSA) are among the co-morbid conditions associated with IPF, specific questions regarding treatment for these conditions were not addressed in the guidelines.**
- **Acute exacerbation of IPF**
 - The majority of patients with acute exacerbation should be treated with corticosteroids, but corticosteroids may not be reasonable in a minority (weak recommendation).
- **Pulmonary hypertension**
 - Echocardiography is not accurate in estimating pulmonary hemodynamics in patients with fibrotic lung disease and should not be relied upon to assess presence and severity of PH.
 - Right heart catheterization is required to confirm presence of PH.
 - Conditional recommendation against treatment of PH in patients with IPF reassessment deferred in 2015 guideline.
 - If treating pulmonary HTN, strong recommendation against using ambrisentan (potential for harm).
- **GERD**
 - Conditional recommendation for anti-acid treatment in patients with IPF (very low confidence).
- **Lung Cancer**
 - No routine recommendation on screening/surveillance imaging can be made based on lack of data.
- **Extrapulmonary manifestations of some genetic forms of IPF**
 - Bone marrow failure, liver disease.

Palliative Care

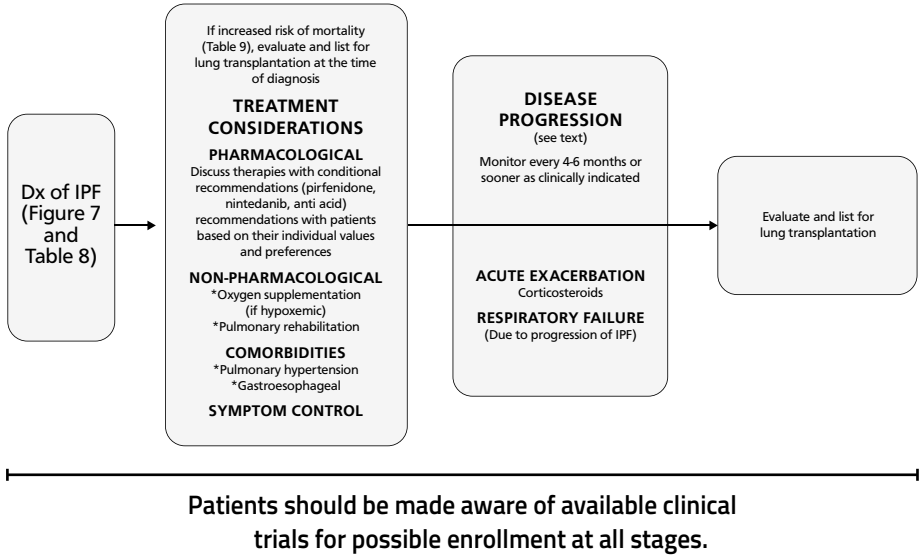
- Palliative care should be considered an adjunct to disease-focused care.
- Corticosteroids and thalidomide may be beneficial for chronic cough.
- Chronic opioids may be used for severe dyspnea and cough with careful monitoring for side effects.
- Advanced directives and end-of-life care issues should be addressed in the ambulatory setting in all patients with IPF, particularly those with severe physiologic impairment and co-morbid conditions.
- Hospice care should be considered for patients who are bed bound due to IPF.

Monitoring the Clinical Course of Disease

- Increasing respiratory symptoms, worsening PFTs, progressive fibrosis on HRCT or acute respiratory decline may be manifestations of disease progression.
- Disease progression is usually monitored over periods of 3-6 months although optimal time interval for repetition of FVC and DLCO has not been formally investigated.
- For patients manifesting acute respiratory worsening, the possibility of acute exacerbation of IPF should be considered and prompt evaluation for alternative etiologies of acute worsening such as pulmonary embolism, pneumothorax, respiratory infection or aspiration should ensue.
- Oxygen saturation at rest and with exertion should be measured at baseline and during follow up at 3-6 month intervals.
 - Desaturation < 88% during formal 6MWT generally used to prescribe supplemental O₂.

Summary of Clinical Management of IPF

Figure 11: Schematic Pathway for Clinical Management of Patients with IPF (Modified from the 2011 Guideline)



Conclusion

This pocket guideline for diagnosis and management of IPF includes evidence based recommendations updated for diagnosis (2018) and treatment (2015) from the 2011 guidelines.

- The panel that made the 2018 recommendations for the diagnosis of IPF recognized the urgent need for future studies to refine and validate diagnostic approaches in ILD. These include investigations into the roles of clinical observations, HRCT, bronchoscopy, histopathology, biomarkers, machine learning tools and genetic testing.
- Further evidence from studies completed since and newer evidence when available will need to be synthesized and discussed by an expert committee and recommendations updated in future guidelines will be incorporated in subsequent versions of this pocket guide.

References

The readership is encouraged to read the original, official ATS documents (guidelines) published in the AJRCCM:

1. Raghu G, Collard HR, Egan JJ. An official ATS/ERS/JRS/ALAT statement: Idiopathic Pulmonary Fibrosis: evidence-based guidelines for diagnosis and management. *Am J Respir Crit Care Med* 2011; 183: 37.
2. Raghu G, Rochweg B, Zhang Y, Cuello Garcia CA, Azuma A, Behr J, Brozek JL, Collard HR, Cunningham W, Homma S, Jonkoh T, Martinex FJ, Myers J, Protzko SL, Richeldi L, Rind D, Selman M, Theodore A, Wells AU, Hoogsteden H, Schunemann HJ. An official ATS/ERS/JRS/ALAT clinical practice guideline: Treatment of idiopathic pulmonary fibrosis. An update of the 2011 clinical practice guideline. *Am J Respir Crit Care Med* 2015; 192: 16.
3. Raghu G, Remy-Jardin M, Myers JL, Richeldi L, Reyerson CJ, Lederer DJ, Behr J, Cottin V, Danoff SK, Morell F, Flaherty KR, Wells A, Martinex FJ, Azuma A. Diagnosis of Idiopathic Pulmonary Fibrosis: An official ATS/ERS/JRS/ALAT Clinical Practice Guideline. *Am J Respir Crit Care Med* 2018; 198: 25.

Additional References

4. Raghu G, Chen SY, Yeh WS, Maroni B, Li Q, Lee YC, Collard HR. Idiopathic pulmonary fibrosis in US Medicare beneficiaries aged 65 and older: incidence, prevalence, and survival, 2001-11. *Lancet Respir Med* 2014; 2: 7.
5. Richeldi L, Wilson KC, Raghu G. Diagnosing idiopathic pulmonary fibrosis in 2018: bridging recommendations made by experts serving different societies. *Eur Respir J* 2018; 52.
6. Raghu G. Idiopathic pulmonary fibrosis: lessons from clinical trials over the past 25 years. *Eur Respir J* 2017; 50.
7. Collard HR, Ryerson CJ, Corte TJ, Jenkins G, Kondoh Y, Lederer DJ, Lee JS, Maher TM, Wells AU, Antoniou KM, Behr J, Brown KK, Cottin V, Flaherty KR, Fukuoka J, Hansell DM, Johkoh T, Kaminski N, Kim DS, Kolb M, Lynch DA, Myers JL, Raghu G, Richeldi L, Taniguchi H, Martinez FJ. Acute exacerbation of Idiopathic Pulmonary Fibrosis. An International Working Group Report. *AJRCCM* 2016; 194: 11.



We help the world breathe[®]
PULMONARY • CRITICAL CARE • SLEEP

SC-US-69626

To improve health worldwide by advancing research,
clinical care and public health in respiratory disease